

Snail Extract Cream in burn scars and grafts

August 2000

Authors:

Maricela González M., M.Pilar Egaña G., Natalia Muñoz., Paz Correa C.

Occupational Therapy Unit, Help Corporation for the burned child, COANIQUEM

The Help Corporation for the burned Child COANIQUEM, is a private, non/lucrative, Chilean entity, who's main concern is focused on the integral rehabilitation of the burnt child. It has two rehabilitation centers, one is located in the community of Pudahuel and another in Antofagasta. Both receive burned children throughout the country, as well as neighboring countries.

Among its many activities: burn prevention seminars throughout the entire country and abroad, out patient treatment in the acute burned, integral treatment of the long term effects due to burns. COANIQUEM through its investigation, extension and academic direction (DEDI), is working on a line of clinical investigation to study a wide variety of products which could possibly favor functional recovery and/or cosmesis in the long-term burn effects.

It is in this line of investigation that, with the authorization of COANIQUEM's ethics committee, a study protocol has been designed to evaluate a product derived from snail extract. With the Chilean Institute of Public Health's authorization, the product is commercialized under the fantasy name of Elicina.

Background

Over millions of years (in the past), snails have been used for medical purposes. Afterwards, they were used as a food source.

In our country some years ago, a family decided to put up a snail farm for commercial food purposes. During the recollection process, which implied cleaning and hand manipulation of the mollusk, soft and lathery skin resulted when contact was made with the snail secretion. Small cuts rapidly healed without infections or scars.

LACOFAR laboratory of Chile (authorized as an external control laboratory by the Chilean Public Health Institute on 6/3/1981) underwent the microbiological analysis that determined the extract's purity.

On June the 3rd, 1994, the Public Health Institute, based on the studies made by LACOFAR laboratory, decided to approve the product's use under the name of Elicina (registry number 36.385). The cream is prepared with an 80% formulation of the extract and 20% excipients.

In 1995, when sought out to discover medical purposes, the Chilean Snail Extract (*Helix aspersa* Muller) was chemically analyzed by CONDECAL laboratory, which is the first quality-control, private, external laboratory in Chile. Authorized in 1978 by the Public Health Institute.

This analysis showed that the extract contains: allantoin, collagen, elastin, glycolic acid and natural antibiotics. All these substances are used today with dermatological conditions such as: dry skin treatment, old skin, preventive skin ageing treatment, sunlight-skin affections, irritated skin soother, etcetera.

Allantoin or 5-Ureidohydantoin, is a degrade product found in the blood and urine of certain mammals and results in the uric acid transformation by the enzyme uricase. It is

mainly used today in a variety of skin care products, personal hygiene and irritated skins, tooth pastes, aftershave cream and lotions, because of its skin repairing action.

Collagen is a protein that's usually obtained from young animal's dermis's connective tissue; it is incorporated into many dermatological and cosmetic preparations to avoid wrinkle formation since it has been proved that the degenerative changes of the skin are motivated by the decrease in the quantity and elasticity properties of the skin's collagen. Due to its low molecular weight, it can be absorbed through local application, retaining this way the necessary protein complex needed for old, worn out skin.

Elastin is the result of hydrolization of elastic proteins, which constitute the fibers that form the elastic tissues and in cosmetology its main use is in the treatment of old skin, which lack elasticity and turgency.

Glycolic Acid- alfa-Hydroxyacetic acid participates in the collagen synthesis as a predecessor of glycine. It can work as a queratoplastic in low concentrations. In higher concentrations, it produces an epydermolysis and an important separation of the corneocytes. Due to its above mentioned characteristics, it is employed as an exfoliative agent and a squammous mechanism regulator for the treatment of dry skin. In dermatology, it has a wide array of use treating affections such as ichthyosis, psoriasis, warts and others.

The snail's extract also contains natural antibiotics that prove very effective against the most commonly found bacterias in human skin infections, such as: Escherichia Coli, Staphylococcus Aureus and Pseudomona Aeruginosa.

Investigative Study

This clinical trial was done in the Occupational Therapy Unit of the Rehabilitation Center for the Burned Child in Santiago, under supervision by the Investigation, Extension, and Academic Direction of COANIQUEM; authorized previously in writing by the participating patient's parents. The trial began on August 1999 and concluded in March 2000.

Material and Methods

It is a controlled, double-blind, clinical essay to evaluate the effects of a snail-extract cream (Elicina) applied in burn scars and grafts, compared to a Novobase cream application.

Patients included in the study

Patients of both sexes were included in the study between August 1st and December 31st, 1999 that complied with the following conditions:

- patients treated in the Occupational Therapy Unit in the Rehabilitation Center of COANIQUEM.
- ages from 1 to 20 years
- parent's or adult guardian's written authorization
- burn scar or graft bearers of any etiology
- scar bearers with more than 6 months evolution
- graft bearers at any evolution stage
- scars localized in head, neck and hands
- the patients could find themselves treated with other methods: compressive bandaging, orthosis, joint rehabilitation, etcetera.

Children excluded in the study

- Children who's scars were already being treated with other creams
- Children with silicone gel treatment

Study dependent variables

- Scar and graft height (in mm)
- Scar and graft texture
- Scar and graft pigmentation
- Secondary effects with cream application

The height of the scar was measured in millimeters, taking into consideration the thickest part. A transparent ruler was used for such purpose.

The scar's texture was evaluated by palpation, the characteristics of the adjacent, unharmed skin zone were taken a reference, as well as the changes in texture of the scar throughout the cream application process.

The scar's pigmentation was evaluated using the unharmed, adjacent skin as reference and the similarity or difference the scar of graft had with this given region.

The subjective evaluation, as far as pigmentation and texture is concerned, were all performed by the same treatment professional (Occupational Therapist), who didn't know what type of cream was being applied.

The patients were divided into two groups at random draw.

- Those treated with Novobase
- Those treated with Elicina

The professionals that participated in this investigation (Occupational Therapists, protocol Medical Director), did not know the identity of the creams, thus avoiding statistical errors encountered later in the results and fulfilling the studies condition of being double-blind.

Every patient received Novobase or Elicina cream, according to the draw done previous to the study. A situation could occur where 3 or 4 consecutive patients all received the same cream and an identical container was used for both creams.

The cream was applied in the same manner in all the patients and all the scars: twice a day for a minimum one-month period and a maximum of three months.

A monthly control was made, with a maximum of three controls, until the patient was released.

The results evaluation, in terms of scar height (in mm), pigmentation, texture were all analyzed without knowing what cream had been applied to each patient. The protocol remained sealed during the results stage and finally opened to reveal which patient had been treated with what cream.

To objectively visualize the differences in the results, obtained from both creams, more clearly the following scores were given out

Scores

0= when no change occurred

1= changes in the scar's height, pigmentation or texture since cream application began until final evaluation.

2= changes in only two variables studied

3= changes manifested by the patient in all three variables studied.

In some cases, standardized photographic control was done upon entering the study and with each control.

The data recollection protocol is shown in table 1

The data was statistically analyzed using the Epi Info Program.

Results

Patient's profiles included in the protocol: In the study period 36 patients were included in the protocol, finished their treatment and showed up regularly to their controls. 18 were treated with Elicina and 18 were treated with Novobase.

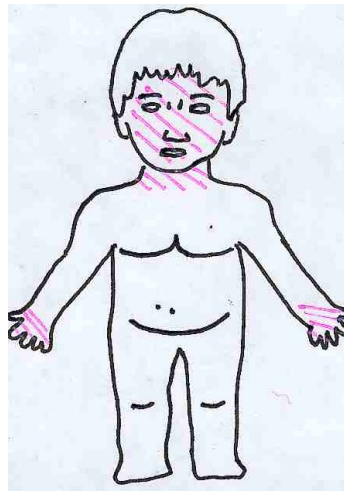
Sex distribution: 20 women and 16 men in the following age groups

Table 1: Age groups

AGES	N*	%
1 to 4 years	20	55,6
5 to 9 years	8	22,2
10 to 14 years	5	13,9
15 and up	3	8,3
TOTAL	36	100

27 patients had burn scars, 28 patients had grafts and 19 patients had scar and graft distribution as seen in Table 2

Table 2: Scar and graft distribution



Distribution	Scar	Graft
	N*	N*
Face	10	6
Neck	5	7
Hands	12	15
TOTAL	27	28

The scar and graft antiquity is seen in Table 3

Table 3: Scar and graft antiquity

Scar antiquity

Months	N*	%
6 to12	10	37.0
13 - 18	8	29.6
19 - 24	2	7.4
25 & +	7	25.9
Total	27	100

Graft antiquity

Months	N*	%
1 to 6	4	14.3
7-12	7	25.0
13-18	9	32.1
19-24	2	7.1
25 & +	6	21.4
Total	28	100

The scar and graft treatment, besides the cream application, in a vast majority included compressive therapy, which were maintained at all times while the cream was used. There were no significant differences among the patients (Elicina/Novobase) with this adjuvant therapy.

One third of the patients received the cream as a sole method of treatment during its application. Compressive or therapy of any other nature could have existed before the cream application.

Table 4:

Concomitant treatment of scars and grafts along with cream application

Type of treatment	N*	%
Compression	16	44.4
Orthesis	1	2.8
Kinesiotherapy	1	2.8
No treatment	9	25
Others	9	25
TOTAL	36	100

Final scores according to cream:

Table 5: Final score according to cream

	SCORE			
	ZERO	ONE	TWO	THREE
ELICINA	1		12	5
NOVOBASE	16	2	0	0
TOTAL	17	2	12	5

Score:

0= no changes

1= difference in scar height, pigmentation or texture (one variable)

2= Changes in only two variables

3= Changes in all three variables

- statistically significant difference with an χ^2 observed of 11.96 and a critical χ^2 of 10.8, α 0,01

Variable changes:

Considering only those pigmentation changes observed after the cream applications, we can see:

Table 6: Pigmentation changes according to the applied cream

	Same Pigmentation	Decreased Pigmentation
ELICINA	4	14
NOVOBASE	17	1
TOTAL	21	15

- 22.2% of the patients that used Elicina maintained their pigmentation. The remaining 77.7%, a decrease was observed.
- Of the patients that used Novobase, 94.4% maintained their pigmentation and only 5.5% showed a decrease.

Table 7: Height changes in scars according to the applied cream

	Same Height	Decreased Height
ELICINA	13	5
NOVOBASE	18	0
TOTAL	31	5

- Those patients that showed a decrease in height, maintained their compressive treatment throughout all the study. 27.7% correspond to those that used Elicina.

Table8: Graft texture changes according to the applied cream

	Same Texture	Decreased Texture
ELICINA	16	2
NOVOBASE	18	0
TOTAL	34	2

- graft texture quality increased in two patients: 11.1% of all patients who used Elicina
- scar texture: no changes were observed with the use of Elicina or Novobase.

Conclusions

The result of this clinical essay concludes that this cream can help in the treatment of burned children with hypertrophic scars and/or grafts, independent of the affected body zone (face, neck and hands). This cream would act favoring loss of pigmentation in scars and grafts and helping the quality of graft texture. Apparently, there wouldn't be any demonstrable effect, in evident relationship as to the hypertrophic scar's height. 27% of the patients treated with Elicina, showed increase in all the evaluated aspects. 66% showed changes in two aspects. 5.5% didn't show any changes whatsoever.

Regarding pigmentation, 22.2% of the patients that used Elicina maintained their actual pigmentation, whereas 77.7% showed decrease. 94.4% of the patients that used Novobase maintained their actual pigmentation and only 5.5% showed decrease.

Considering texture, 11.1% of the patients that used Elicina showed better quality graft results. No changes were observed in scars with the use of either cream.

The scar height decreased in 27.7% of the patients treated with Elicina (percentage associated with compressive treatment).

No side effects whatsoever were observed using Elicina.

Comments

44.4% of the universe of the studied patients maintained compressive therapy throughout the entire study. All of the patients, in which hypertrophic scar height was observed to decrease, were also under compressive treatment.

The use of this cream during the active phase of recent scars and grafts, should be used in conjunction with compressive, adjuvant treatment.

According to the observed results, it seems interesting to us to conduct a new study in which Elicina is applied to patients who possess older grafts and mature scars and who don't require compressive therapy. in order to be able to truly isolate the studied variables.

ELICINA PROTOCOLS INFORMATION

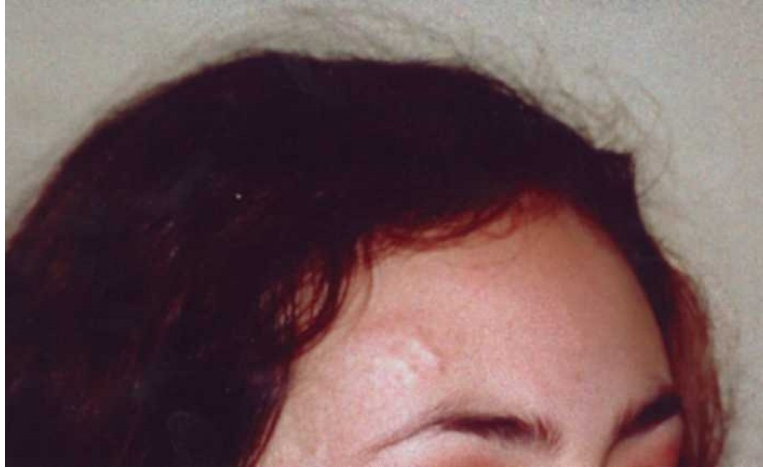

Photo 1

Female 20 years old when she was included

Photo 1: Sept. 27, 1999: hyaline scar, thickened and soft

Photo 2: Jan 14, 2000: soft, flat scar, similar color compared to normal skin
· without any additional treatment, except elicina

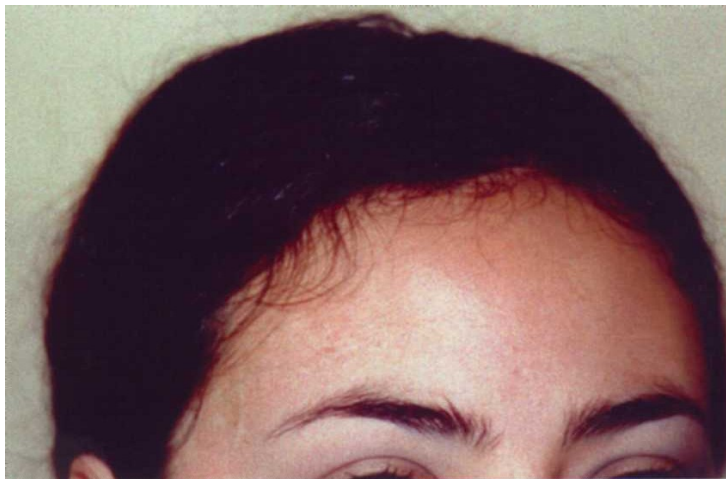

Photo 2

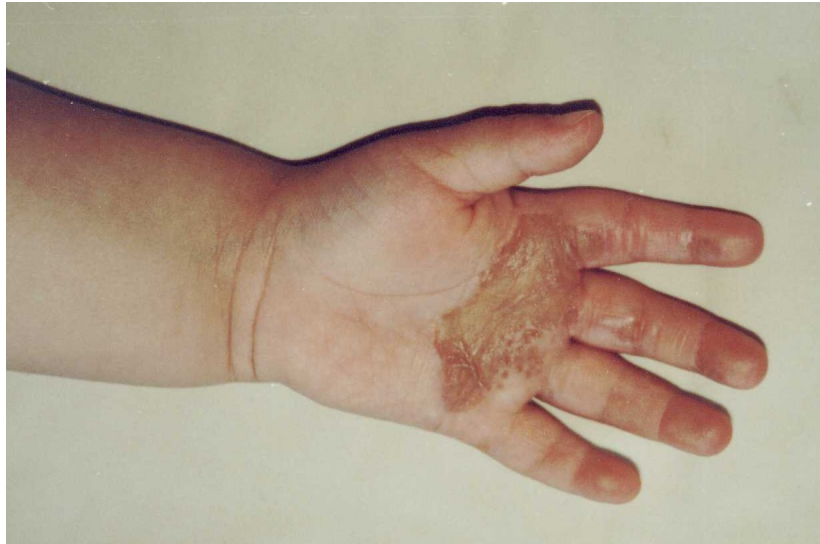

Photo 1

Female, 2 years 6 months old.

Photo 1: Sept 30, 1999: soft scar ruffled graft

Photo 2: Oct 27, 2000: soft scar, soft graft, diminished coloration, light-brown.
· night compressive treatment associated with Elicina

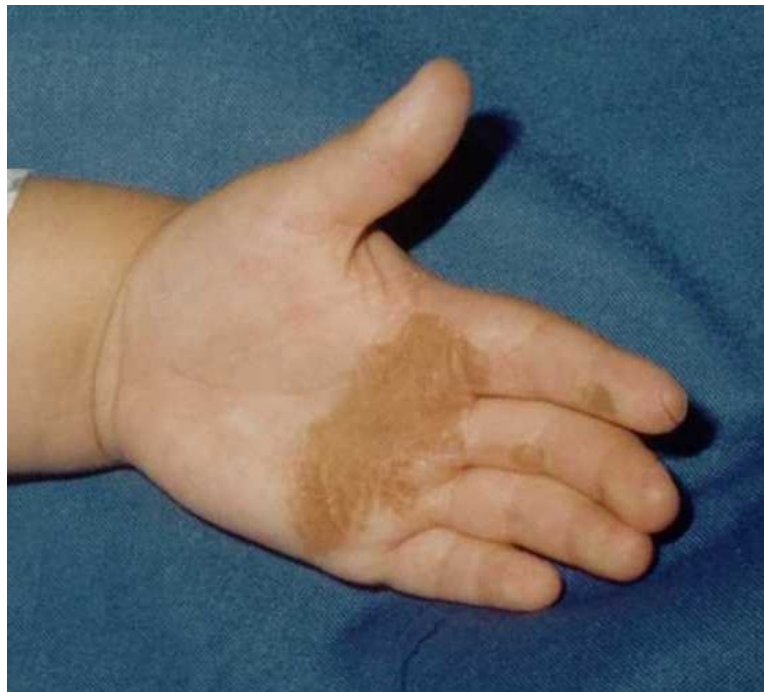

Photo 2

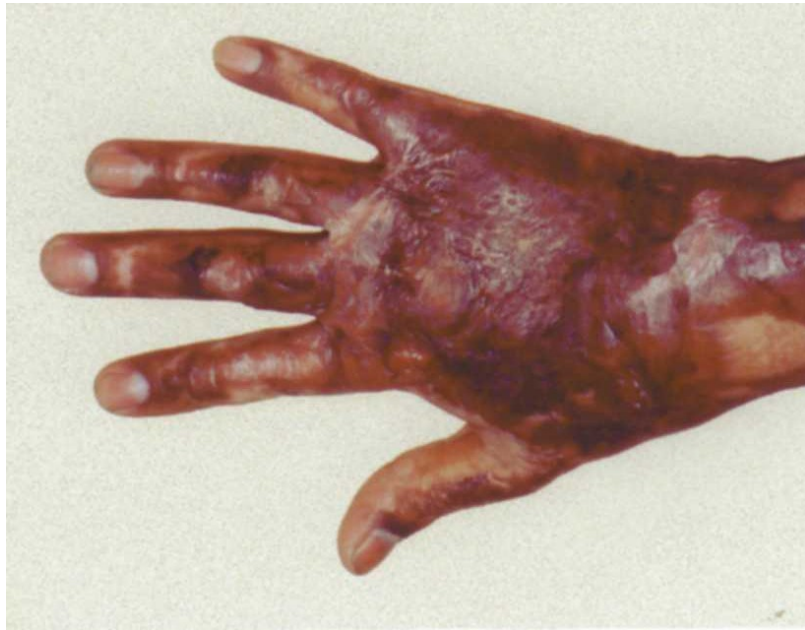

Photo 1

Male 20 years old.

Photo 1: Oct 4, 1999: soft scar, graft very anfractuous, dark-brown color

Photo 2: Nov 30, 1999: soft scar, soft graft, anfractuousity clearly decreases, decreased coloration

· parallel compressive treatment to Elicina.

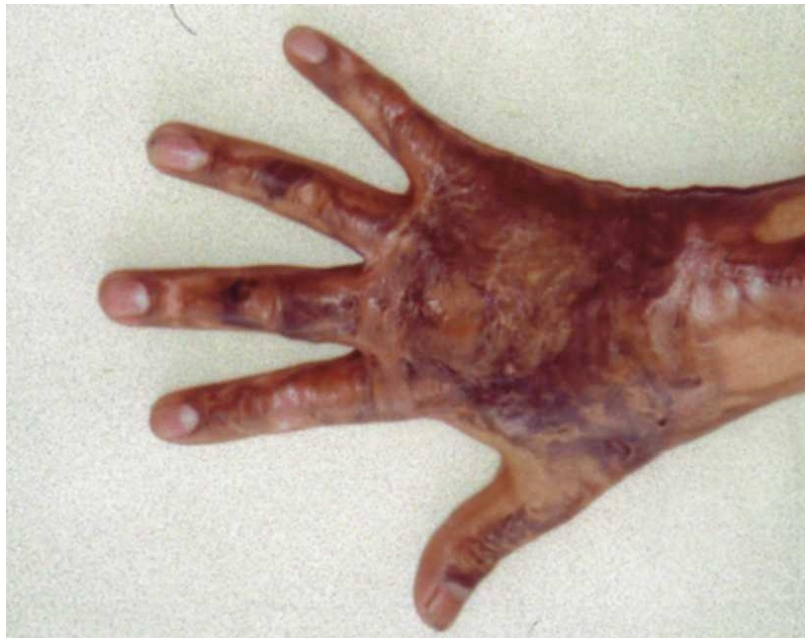

Photo 2

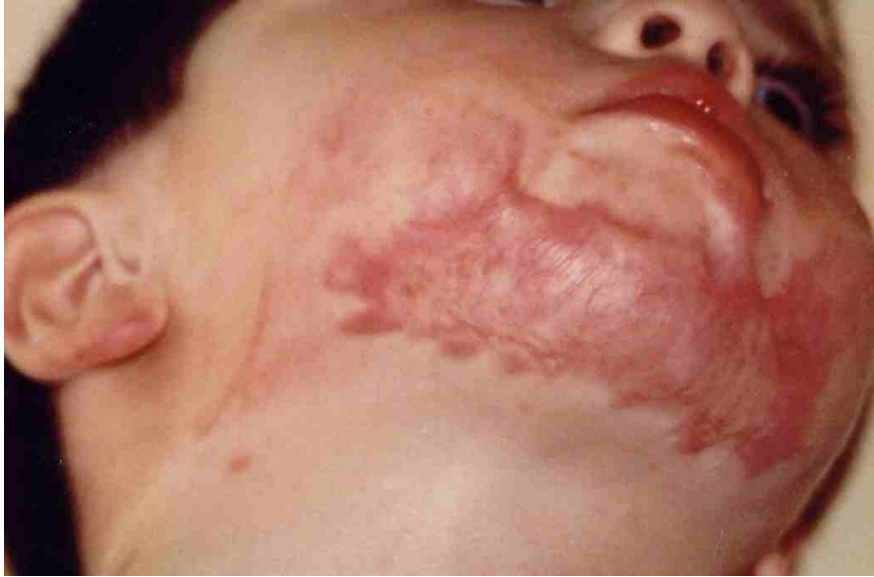

Photo 1

Male, 2 years, 3 months old.

Photo 1: Nov 30, 1999: Soft scar, 2 mm thick, anfractuous soft graft

Photo 2: Oct 27, 2000: soft scar, coloration evidently decreases, thickness decreases throughout its major surface, anfractuous soft graft, light-beige color

· Compressive permanent treatment parallel to Elicina application.

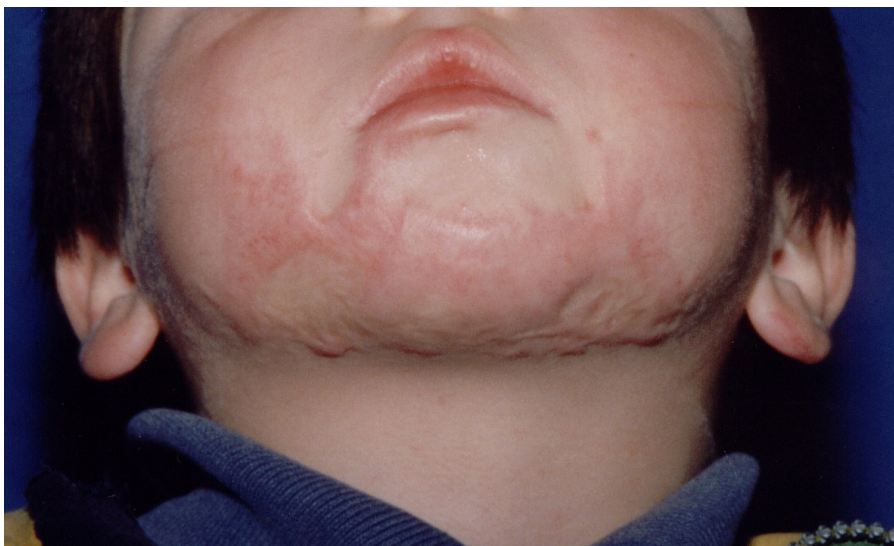

Photo 2

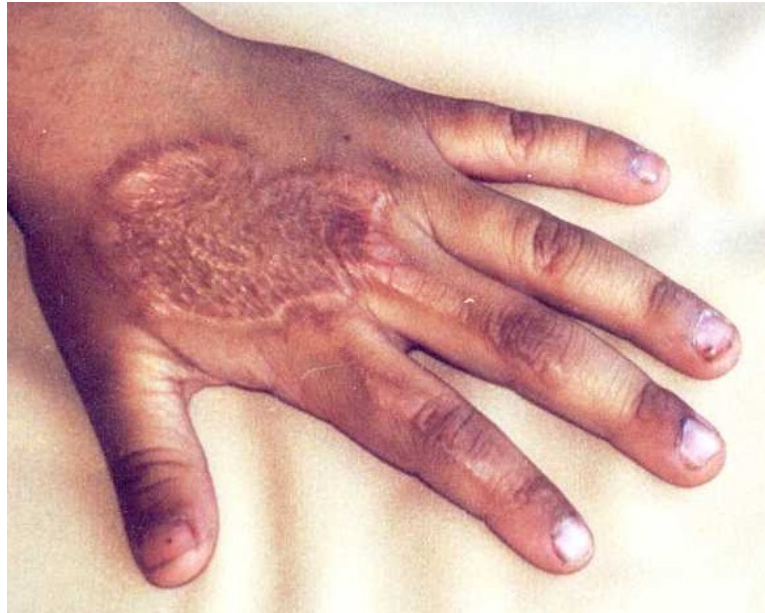

Photo 1

Female, 3 years old.

Photo 1: Oct 27, 1999: soft scar, soft and anfractuous graft

Photo 2: Dic 23, 1999: soft scar, volume decreased graft

· No additional parallel treatment besides Elicina

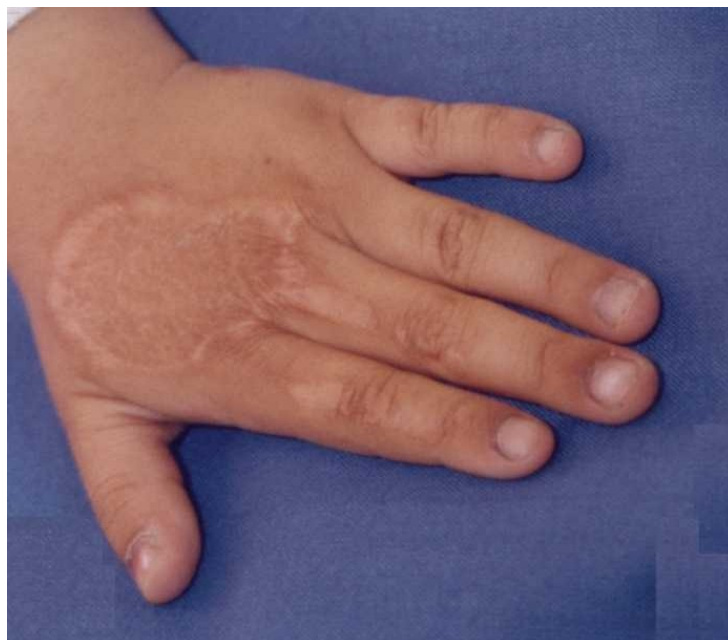

Photo 2